

MEASUREMENT OF THE CROWN LENGTH OF CHEEK TEETH IN CLINICALLY HEALTHY RABBITS

M. Schumacher

Introduction:

Rabbits' teeth grow continuously. Any discrepancy between growth rate and wear usually results in a change of tooth length. If there is decreased wear due to a painful process, malocclusion or dietary imbalances there is going to be an increase in tooth length.

So far there are only vague statements in literature regarding on length of molars in clinically healthy rabbits. In the lower jaw 'several mm' and in the upper jaw 'a few mm' are given as standard crown length (Gorrel, 2004; Eickhoff, 2005). The goal of this study was to determine the crown length of molars in rabbits without clinical signs of dental disease.

Anatomically/ Clinically and Radiologically Relevant Criteria for Measuring the Length of Exposed Tooth Crowns

Teeth:

- hypsodont: The tooth consists of a short exposed or clinical crown and a long reserve or submerged crown. The root is open and is also called the germinative zone (aradicular tooth)
- elodont: continuous growth
-

Permanent Dentition:

28 teeth 2x (I_{2/1}: C_{0/0}: P_{3/2}: M_{3/3})

Dental Growth:

The incisors grow in a curve. The growth rate of the upper incisors is 2mm per week and of the lower incisors about 2.4mm per week. The molars grow vertically at a similar speed.

Alveolar Crest:

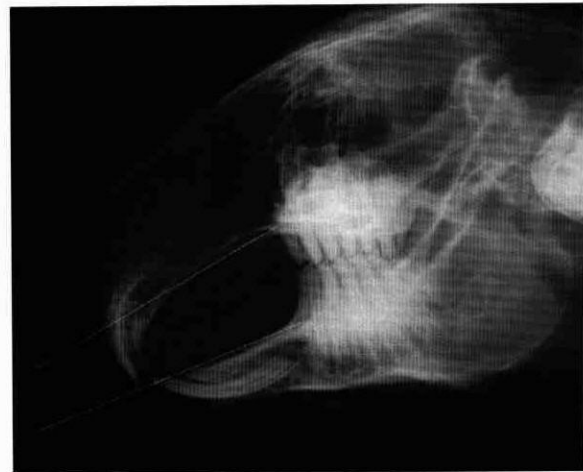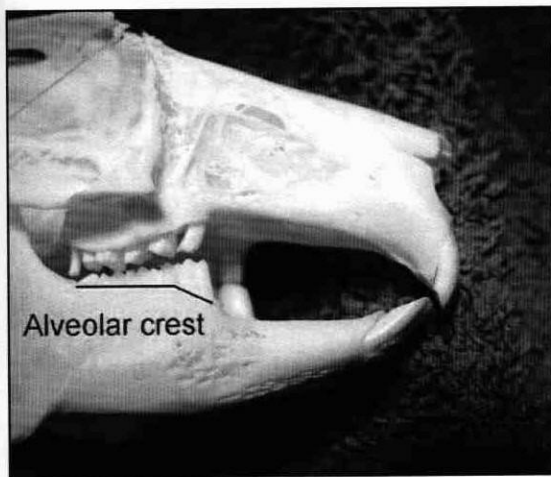
*little slower growth
back*

The alveolar crest slopes from the P₄ towards the P₃ rostrally so that the P₃ has got a slightly longer exposed crown than the other molars in the lower jaw (Figure 1).

Occlusion:

The incisors of the lower jaw occlude between the first and second incisors (peg teeth) of the upper jaw. The molars have got enamel folds which are characteristic for herbivores, i.e. on the occlusal surface there are enamel, dentin and cement side by side (same as in the horse).

Due to uneven wear a characteristic relief develops because of which food can be ground better. The occlusal surfaces are tilted at a 10° angle laterally due to anisognathia, i.e. the upper jaw is wider than the lower jaw.



Adspection of Incisors and Molars:

For our study it was very important to know what the dentition of a normal rabbit looks like on adspection and radiographically (Figure 2). Healthy teeth should show the following characteristics on adspection as listed in Table 1.

Table 1

Incisors	Cheek teeth
The upper I have got vertical grooves on the labial surface	The exposed crowns of the upper molars show only 'a few' mm above the gingiva
In occlusion the lower I's rest between the upper I's	The exposed crowns of the lower molars show 'several' mm above the gingiva
The occlusal surface is horizontal	The occlusal surfaces show a 10° angle laterally
The crown is chisel-shaped	No sharp points/hooks

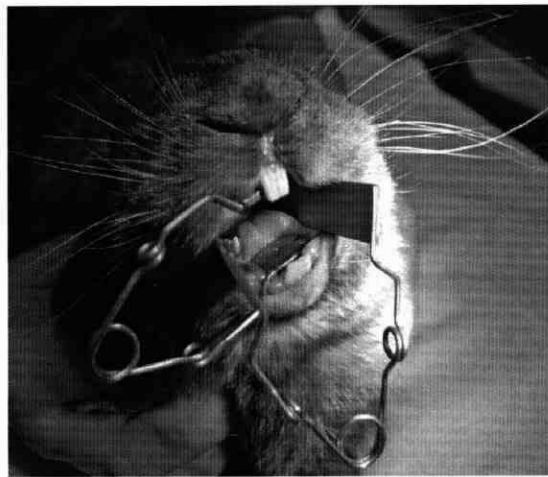
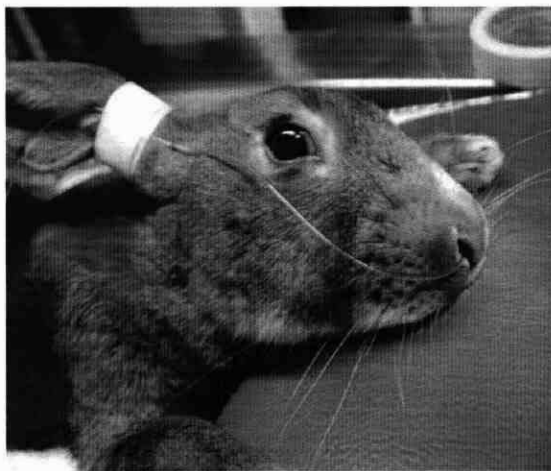
Radiographically important characteristics are listed in Table 2.

Table 2

Laterolateral View	Rostrocaudal View
The hard palate and the dorsal border of the mandible converge rostrally	The occlusal surfaces are nearly horizontal
Ideally when the incisors are in occlusion the molars should not be in occlusion	No sharp points/hooks
Periapically there is a radiolucency	

Material and Methods

In our surgery and the small animal practice Rieker & Bohnenberg, Ravensburg, in 20 male rabbits aged 4-15 months that were anaesthetised for castration the length of the molars was measured. The patients were anaesthetised using injection anaesthesia according to Erhard and Henke (2004). If necessary Oxygen was given via an intranasal catheter (Figure 3). The mouth was opened with 2 cheek spreaders (Figure 4). The other instrument used was a plastic spatula to divert the tongue.



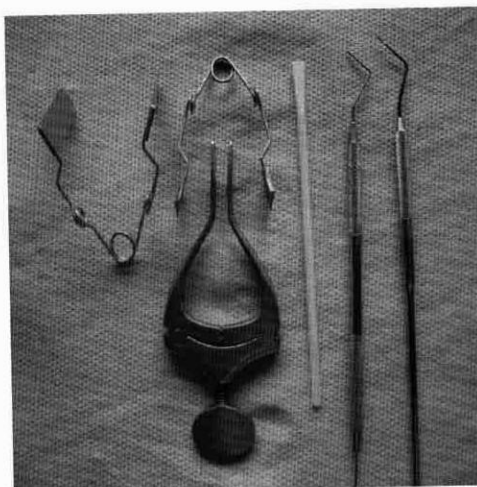
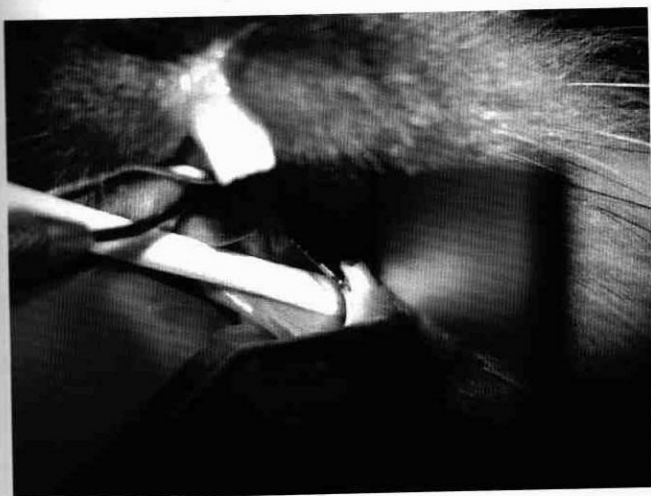Measurement Points:

- P₃,P₄ in the lower jaw
P₂ in the upper jaw
- at the same time the periodontal probing depth (ppd) of those teeth was measured (Figure 5)
- if possible, the measurements were taken lingually and buccally

Whilst taking measurements the crowns were checked for sharp points or hooks. With uneven wear sharp points develop lingually in the lower jaw and buccally in the upper jaw.

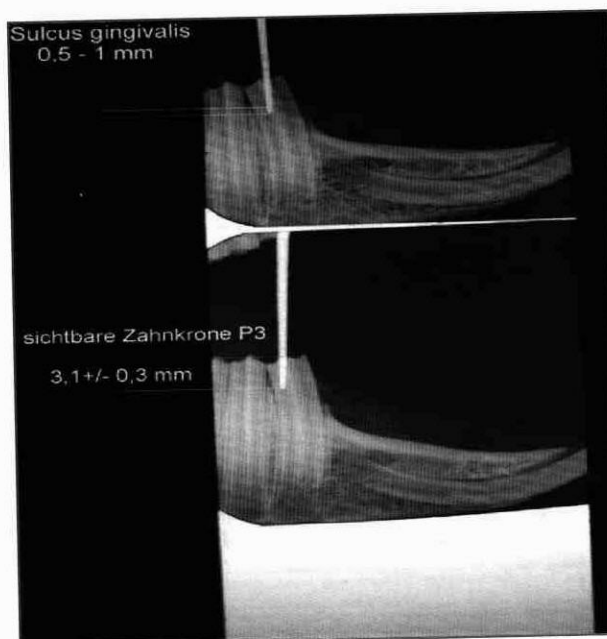
Gauge:

- Schwert periodontal probe 1-2-3-4-5-6-7-8-9-10mm
- Modified periodontal probe 1-2-3-4-5-6-7-8mm (Figure 6)



Results





We measured the crown length of 120 cheek teeth and the same amount of Sulcus depth in total. In the 20 animals examined the crown length of the lower P₃ varied from 2.5-4mm. The average crown length of the lower P₃ was 3.1 +/- 0.3mm. The lower P₄ showed a crown lengths from 2-3mm with an average of 2.6 +/- 0.4mm. The lengths measured at the upper P₂ were in a range of 1-2.5mm and the average length was 1.5 +/- 0.4mm. The ppd in the upper and lower jaw was very similar. The ppd varied from 0.5-1mm (Figure 7).



In 40% of the examined animals (n=8/20) no visible hooks or points were found. 60% of animals (n=12/20) did show clinically visible hooks/points which were directed lingually in the lower jaw and buccally in the upper jaw. 42% of patients (n=5/12) with hooks/points had not shown any clinical signs of dental disease a year after the measurements had been taken. The other 58% of patients (n=13) were not available for a check up. The median age was 6.4 months. The rabbits in the study weighed 1-2.5kg with an average weight of 1.5 +/- 0.3kg. The hooks/ sharp points were classed into Grade I, II, III.

The criteria are shown in Table 3.

Table 3

Lower cheek tooth	Exposed Crown	Reserve Crown	Root
Normal 	-about 10° angle laterally -no sharp points	-no curvature -no elongation	-pointed
Grade I 	-greater angle laterally -elongated -small sharp points	-no curvature -apically no or slight elongation	-pointed
Grade II 	-even greater angle -elongated -curved -hooks/ sharp points evident	-curved -apically elongated	-shortened -deformation possible
Grade III 	-as in Grade II with all changes more prominently displayed	-as in Grade II with all changes more prominently displayed	-normal shape not evident anymore

Discussion

In our study only 40% of examined animals did not show any clinical changes of the teeth. This percentage is similar to the one shown in a study done by Gabriel, S (2002) of 31.5%. Whether dental treatment of sharp points/hooks without clinical symptoms is appropriate remains questionable. 42% of patients with sharp points/hooks had not shown any clinically obvious dental problems a year after the measurements had been taken without dental treatment. According to Crossley (2001) dental changes in rabbits are common without the appearance of clinical symptoms. He advises against treating those patients.

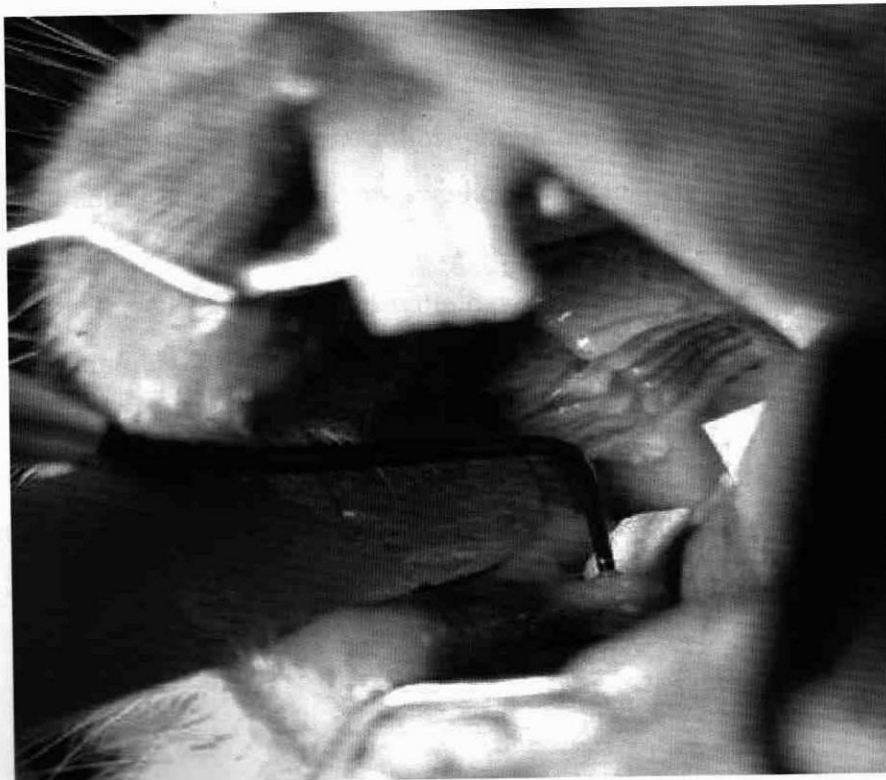The degree of crown elongation in conjunction with dental disease has got to be the topic of further studies. In one publication about the pathophysiology of dental growth Crossley (2001) mentions that in continuously growing teeth there is not just an increase in length of the crown but also of the periodontal tissue and alveolar bone. This would mean that the exposed crown does not appear to be elongated optically.

Resume

- Measuring the crown length and the ppd should be integrated into the examination
- Measurements of the crowns of the rostral molars and ppd are easy to do in the rabbit with a periodontal probe
- The measurements can be used as a reference when trimming molars
- The divergence in tooth length in the individual animals is minimal

As in cats and dogs an increased ppd is an obvious clinical sign of periodontal disease (Figure 8). In another study in rabbits with dental problems it will be examined whether and how the crown lengths changes in comparison to healthy young animals.

My special thanks go to Ms Nicole Dorn, DVM, from the small animal practice Rieker&Bohnenberger in Ravensburg for the help with taking measurements of crown lengths and checking through this manuscript.



References

- Böhmer E, Köstlin RG, 1988: Zahnerkrankungen bzw. -anomalien bei Hasenartigen und Nagern. *Prakt. Tierarzt* 69 (11), 37-50, Crossley DA, 1995: Clinical Aspects of Lagomorph Dental Anatomy: The Rabbit (*Oryctolagus cuniculus*). *J. Vet. Dent.* Vol. 12 (4), 137-140, Crossley DA, 2001: Burring elodont cheek teeth in small herbivores. *Vet. Record* 148 (21), 671-672, Crossley DA, 2001: Pathophysiology of continuous growing teeth in small pets. *Proceedings 47. Annual Congress FK-DVG Berlin*, 57-60, Crossley DA, 2003: Oral biology and disorders of Lagomorphs. *Vet. Clin. Exot. Anim.* 6, 629-659, Eickhoff M, 2005: Heimtiere. Zahn-, Mund- und Kieferheilkunde bei Klein- und Heimtieren, Enke Verlag Stuttgart, 223-235 Ewringmann A, 2005: Leitsymptome beim Kaninchen. Enke Verlag Stuttgart, 9-27, Gabriel S, 2002: Zwergkaninchen als Zahnpatienten in der tierärztlichen Sprechstunde, *Prakt. Tierarzt* 83 (3), 238-242, Gorrel C, 2004: Dental diseases in lagomorphs and rodents. *Veterinary Dentistry for the General Practitioner*, Saunders Elsevier London, 175-196; Harcourt-Brown FM, 1995: A review of clinical conditions in pet rabbits associated with their teeth. *Vet. Record* 137 (14), 341-346; Harcourt-Brown FM, 1998: Kaninchen als Heimtiere: Häufige klinische Probleme. *Waltham Focus* 8 (4), 6-13; Henke J, Erhardt W, 2004: Allgemeinnarkose bei Nagern und Kaninchen. *Bpt Nürnberg: Kongreßband Kleintiere*, 187-198; Henke J, Reinert J, 2006: Anwendung von Medetomidin in der Heimtierpraxis. *Fachpraxis Nr. 50*, 12-19; Hollmann P, 1992: Verdauungsstörungen bei Kaninchen und Meerschweinchen. *Tierärztl. Praxis* 20, 557-571; Lobprise HB, Wiggs RB, 1991: Dental and oral disease in Lagomorphs. *J. Vet. Dent.* Vol.8 No.2, 11-17; Quesenberry KE, Carpenter JW, 2004: Basic Anatomy, Physiology and Husbandry. Ferrets, Rabbits, and Rodents, *Clinical Medicine and Surgery* Second Edition, Saunders Elsevier (USA), 136-146; Schumacher M, 2006: Zahnbehandlung beim Kaninchen Teil 1. *Fachpraxis Nr. 49*, 22-25; Schumacher M, 2007: Messung der Länge von Backenzahnkronen beim gesunden Kaninchen. *Proceedings 3. Annual Congress of the German Veterinary Dental Society in Berlin*, 5-6; Taglinger K, König HE 1999: Makroskopische-anatomische Untersuchungen der Zähne des Kaninchens (*Oryctolagus cuniculus*). *Wien. Tierärztl. Mschr.* 86, 129-135; Verstraete FJM, Osofsky A, 2005: Dentistry in Pet Rabbits. *Comp. Cont. Educ. Pract. Vet.* Vol. 27 (9), 671-683